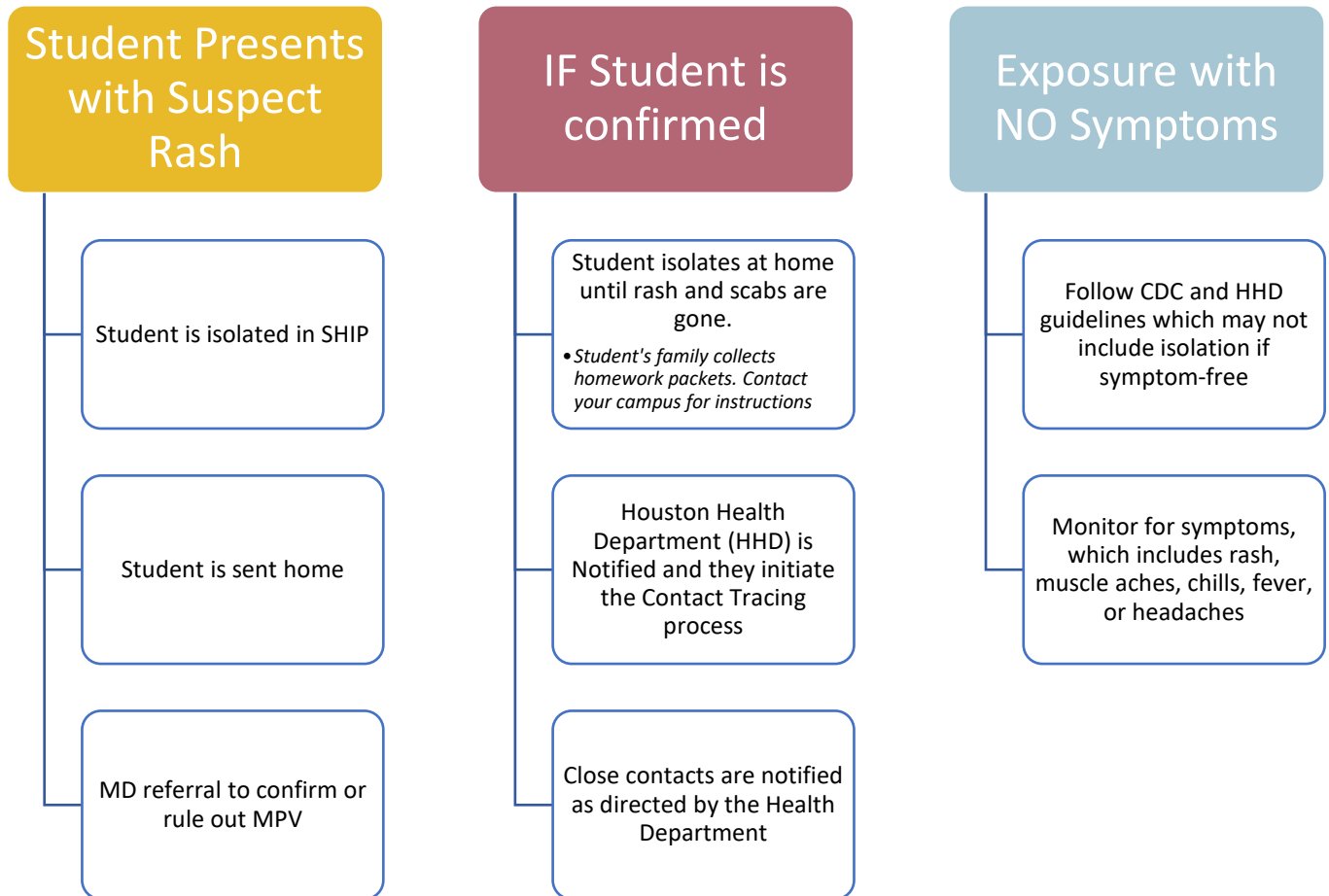
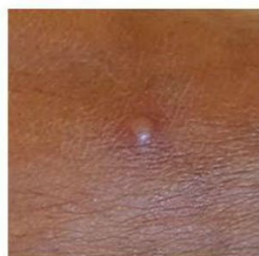

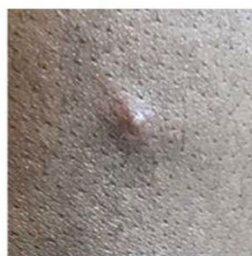## Monkey Pox Virus (MPV) Flowchart



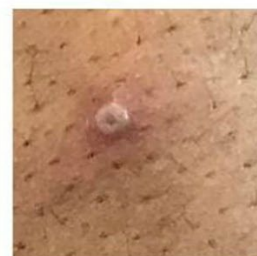***Student Confidentiality is imperative. No Student should be identified as having MPV***



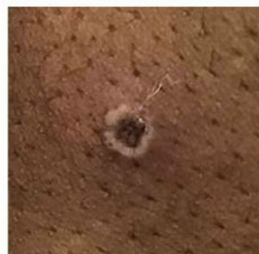a) early vesicle,  
3mm diameter



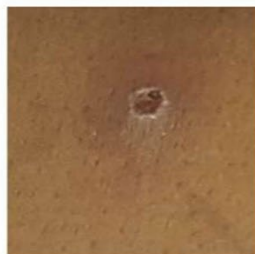b) small pustule,  
2mm diameter



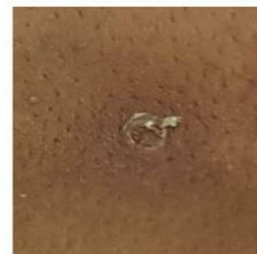c) umbilicated pustule,  
3-4mm diameter



d) ulcerated lesion,  
5mm diameter



e) crusting of a mature  
lesion



f) partially removed  
scab